



An analysis of a case with pulmonary aspergillosis and recurrent hemoptysis

Ramyasri¹, Boini meghana², Gorre madhavi², Pisikala mounika², Ranga pushpa²,
Nakaranti navya²

¹Department of Pharmacology, St. Mary's group of institution, Deshmukhi (Village), Pochampally (Mandal), Yadadri Bhuvanagiri (Dist), Telangana-508284, India

²St. Mary's group of institution, Deshmukhi (Village), Pochampally (Mandal), Yadadri Bhuvanagiri (Dist), Telangana-508284, India



Article History:

Received on: 01 May 2023
Revised on: 18 May 2023
Accepted on: 19 May 2023

Keywords:

Pulmonary aspergillosis,
Hemoptysis,
Lung ailments,
Fungal Infection

ABSTRACT

Among the several Invasive pulmonary aspergilloses is one of the clinical manifestations of the condition, allergic bronchopulmonary aspergillosis, aspergilloma, chronic cavitary pulmonary aspergillosis, and chronic necrotizing aspergillosis. Hemoptysis is a severe pulmonary aspergillosis complication that frequently requires surgery. We report a 52-year-old man who had diabetes mellitus and pulmonary tuberculosis in the past, and hemoptysis when he arrived with a productive cough and hemoptysis for two months. Chest computed tomography revealed an upper lobe soft tissue mass with a diameter of 30 mm. Two weeks following the original episode, the patient experienced a further episode of chronic hemoptysis that bronchial arterial embolization could only partially treat. The centre and upper right lobes were eliminated. A histological analysis determined that the disease was a fungal cavitary lesion. At the 18-month checkup, the patient had fully healed after beginning voriconazole and had no recurrence.

*Corresponding Author

Name: Ramyasri
Phone: +91 8008993828
Email: ramya.shivarla@gmail.com

eISSN: 2583-116X

pISSN:

DOI: <https://doi.org/10.26452/fjphs.v3i2.465>



Production and Hosted by
Pharmasprings.com
© 2023 | All rights reserved.

INTRODUCTION

Aspergillosis pulmonary refers to the clinical range of lung conditions brought on by different *Aspergillus* species. These fungal infections have become more common recently and are associated with significant rates of morbidity and mortality. Aspergillosis is still challenging to diagnose in clinical settings despite the documented clinical

effects and advances in diagnostics. In this article, we discuss a patient who had previously experienced pulmonary tuberculosis and who later got pulmonary aspergillosis that was made worse by hemoptysis (TB).

Case report

A 52-year-old man with a severe cough and a two-month history of hemoptysis showed up. He downplayed every symptom, including the fever, chills, night sweats, chest pain, and shortness of breath [1]. At the age of 48, he had a history of pulmonary TB and type 2 diabetes. He had been a smoker for 30 years, having stopped in his mid-20s, and he denied using alcohol or other drugs. Physical examination revealed normal vital signs, and a chest x-ray detected sporadic crackles in the right upper lung region. The remainder of the physical exam consisted of uneventful [2].

Investigations

The test results, other than a chance blood glucose

value of 242 mg/dL, were normal [3]. An acid-fast bacillus (AFB) smear and culture were unfavourable on three samples of sputum. The HIV test was also unfavourable.

In the right upper lobe of the chest's CT scan [Figure 1], a soft tissue mass with a diameter of 30 mm was surrounded by a significant infiltration. Other bronchoalveolar lavage tests, such as the cytology for cancer cells, AFB smear and culture, Grocott's methenamine silver (GMS), as well as were negative. A video bronchoscopy revealed no tracheobronchial abnormalities. Only inflammation was found in the bronchial tissue after a biopsy [4-6].

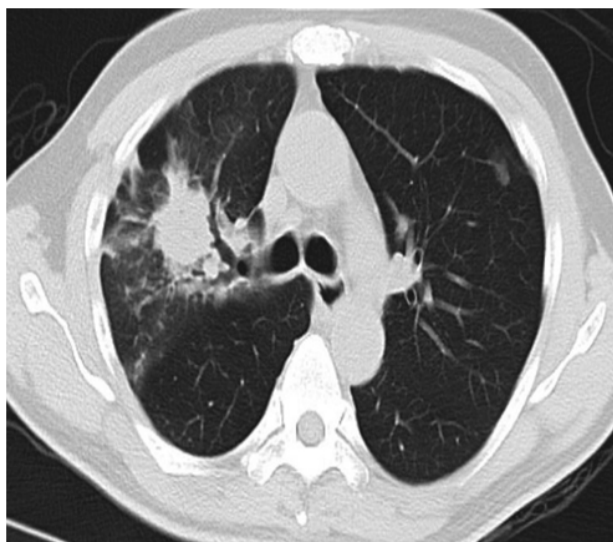


Figure 1: Right upper lobe tumour encircled by an infiltrate as shown on a chest CT

Results and follow-up

Throughout the patient's seven-day hospital stay, the patient achieved clinical progress while maintaining stable vital signs and a normal hemoglobin/haematocrit level. He was returned to the pulmonary clinic for more tests and rigorous supervision.

Two weeks after being discharged, the patient had chronic hemoptysis, and bronchial arterial embolization was performed. Nevertheless, embolization only partially stopped the bleeding. Since being originally examined, the patient's haemoglobin level has decreased by more than 3 g/dL. The surgical surgery for the recurring hemoptysis was agreed to go with. There were no pulmonary function tests (PFTs) performed because of the urgency. However, a preoperative flexible bronchoscopy indicated bleeding from the right middle lobe despite the absence of endobronchial lesions being apparent. Incisions were made in the patient's right upper as well as middle lobectomies.

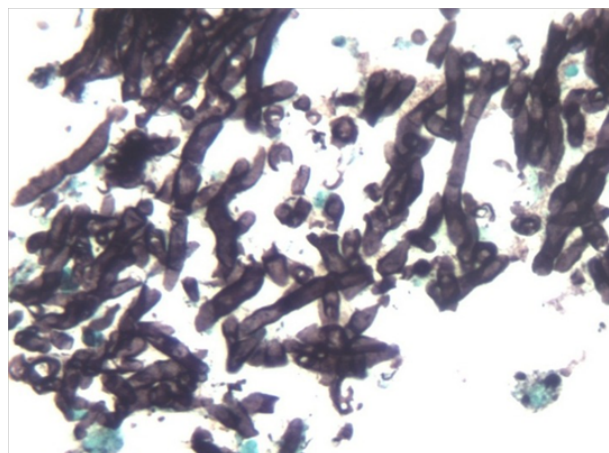


Figure 2: Fungal hyphae are visible on the Grocott-Gomori methenamine silver (GMS) stain in this histopathological image (400)

During operation, 200 mL of blood was thought to have been lost. The patient received three units of packed red blood cells. His haemodynamic and respiratory conditions remained stable following the procedure, and he was transferred to the surgical intensive care unit. His postoperative recovery was hampered by a fever, but it was managed with empiric broad-spectrum antibiotics. Voriconazole was also prescribed to him just after surgery. On the 22nd postoperative day, he was discharged from the hospital.

Histological investigation revealed a cavitary lung lesion with a mass of fungal hyphae that morphologically matched *Aspergillus* spp. on GMS and periodic acid-Schiff (PAS) stains (Figure 2). This was further confirmed through fungus culture. The AFB smear came out negative and there was no evidence of tissue invasion.

Before returning to regular checkups, the patient underwent weekly examinations for the first two months, followed by examinations every two months for the following six months. The use of voriconazole was discontinued after two months. At the 18-month checkup, he had completely recovered and there had been no recurrence. Total lung capacity (TLC) was 3.42 L (57%), forced vital capacity (FVC) was 2.52 L, forced expiratory volume in one second (FEV1) was 1.46 L (43%) and FEV1/FVC was 58%, all of which demonstrated a mixed obstructive and restrictive basis for a moderate ventilatory restriction. Diffusing capacity (DLco) reduced as well (12.3 mL/mm Hg/min; 44% of predicted) with a corrected diffusing capacity (DLco) for alveolar volume (DLco/VA) of 38%. After the bronchodilator, no discernible alterations were observed.

Discussion

This incident highlights how challenging it can be to detect pulmonary aspergillosis. TB, aspergillosis, and malignancy were the three most common differential diagnoses at the time of hospitalisation. The patient's history of tuberculosis (TB), which can coexist with aspergillosis and present in quite similar ways, confounded the diagnosis. The fact that neither the bronchoscopy nor the chest CT revealed the telltale sign of an *Aspergillus*-colonized cavity supports the correctness of the diagnosis. Only by an invasive surgical procedure could the necessary histology samples be collected, and only then was it feasible to confirm the clinical form and make the final diagnosis. This case provides as an illustration of the need for prompt diagnosis and treatment of aspergillosis in order to prevent further complications.

Some of the Aspergilloma, invasive pulmonary aspergillosis, chronic necrotizing aspergillosis (subacute invasive pulmonary aspergillosis), chronic cavitary pulmonary aspergillosis (CCPA), and allergic bronchopulmonary aspergillosis are clinical manifestations of pulmonary aspergillosis. The differential diagnosis of distinct variants can occasionally be difficult due to overlapping signs. The case described here was an aspergilloma and met the description of a simple aspergilloma rather than a CCPA as defined elsewhere since the patient had just one lung cavity, minimal symptoms, and no radiological indications of development.

The clinical symptoms of pulmonary aspergillosis are greatly influenced by the presence of an underlying lung disorder and the health of the immune system. Aspergilloma is a common symptom in patients without immunosuppression who have a history of pulmonary TB or similar cavitary lung condition. A significant fraction of people with aspergillosis are thought to have pulmonary TB, which is expected to cause 1.2 million cases of chronic pulmonary aspergillosis after TB.

Hemoptysis, which happens in 64%–83% of individuals with aspergilloma, is one of the most serious adverse effects of pulmonary aspergillosis. Bronchial artery embolization has been used to reduce significant bleeding, although the results are typically insufficient. It is suggested to use it as a temporary fix to stabilise a patient who is bleeding significantly and may be a candidate for a more long-term solution, like surgery. Acute respiratory distress syndrome, bronchopleural fistulae, empyema, extended air leak, and respiratory failure necessitating tracheostomy/reintubation are all complications associated with surgical resection, which

offers a permanent cure for aspergilloma but is a difficult treatment.

Their pulmonary function may also be harmed if they are unsuccessful surgical candidates. Surgery indications are still a contentious topic recommended surgery only be utilised for individuals with unilateral localised disease, failure of medicinal including hemoptysis in a recent report of 30 patients. Of these 30 patients, 60% had chronic cavitary pulmonary aspergillosis and 40% had treatment, as well as to address issues simple aspergillosis.

It is typically not removed by surgical intervention since antifungal therapy can be utilised to prevent both *Aspergillus* empyema and a return of aspergillosis as an adjuvant therapy post-surgery.

The attempt to stop the bleeding in our case by arterial embolization was only partially successful. The only kind of treatment that ended successfully was surgery.

CONCLUSION

Aspergilloma, allergic bronchopulmonary aspergillosis, invasive Chronic necrotizing aspergillosis, chronic cavitary pulmonary aspergillosis, as well as pulmonary aspergillosis were some of the clinical manifestations of pulmonary aspergillosis. The severe adverse effect of pulmonary aspergillosis known as hemoptysis frequently necessitates surgery. We present the case of a 52-year-old man who had diabetes mellitus, pulmonary TB, a two-month history of hemoptysis, and a persistent cough. A 30 mm diameter soft tissue mass was discovered by chest computed tomography in the right lung's upper lobe. The patient encountered another episode of chronic hemoptysis two weeks following the initial incidence, which bronchial arterial embolization could only partially manage. The upper and middle lobes of the right side were removed. A fungus cavitary lesion was discovered by histological analysis. After starting voriconazole, the patient had fully recovered at the 18-month check-up.

ACKNOWLEDGEMENT

I would like to thank Principal sir (Dr. Kamal Hassan) St. Mary's Group of Institutions, Deshmukhi (Village), Pochampally (Mandal), Yadadri Bhuvana-giri(Dist), Telangana-508284, India.

Conflict of Interest

The authors attest that they have no conflict of interest in this study.

Funding

No Funding.

REFERENCES

- [1] George R Thompson and Thomas F Patterson. Pulmonary aspergillosis: recent advances. *Seminars in Respiratory and Critical Care Medicine*, 32(6):673–681, 2011.
- [2] Thomas J Walsh, Elias J Anaissie, et al. Infectious Diseases Society of America. Treatment of aspergillosis: clinical practice guidelines of the Infectious Diseases Society of America. *Clinical Infectious Diseases*, 46(3):327–360, 2008.
- [3] N L Smith and D W Denning. Underlying conditions in chronic pulmonary aspergillosis including simple aspergilloma. *The European Respiratory Journal*, 37(4):865–872, 2011.
- [4] David W Denning, Alex Pleuvry, and Donald C Cole and. Global burden of chronic pulmonary aspergillosis as a sequel to pulmonary tuberculosis. *Bulletin of the World Health Organization*, 89(12):864–872, 2011.
- [5] Shakil Farid et al. Results of surgery for chronic pulmonary aspergillosis, optimal anti-fungal therapy and proposed high risk factors for recurrence-a National Centre's experience. *Journal of Cardiothoracic Surgery*, 8:180–180, 2013.
- [6] J Jewkes, P H Kay, M Paneth, and K M Citron. Pulmonary aspergilloma: analysis of prognosis in relation to haemoptysis and survey of treatment. *Thorax*, 38(8):572–578, 1983.

Copyright: This is an open access article distributed under the terms of the Creative Commons Attribution-NonCommercial-ShareAlike 4.0 License, which allows others to remix, tweak, and build upon the work non-commercially, as long as the author is credited and the new creations are licensed under the identical terms.

Cite this article: Ramyasri, Boini meghana, Gorre madhavi, Pisikala mounika, Ranga pushpa, Nakarakanti navya. **An analysis of a case with pulmonary aspergillosis and recurrent hemoptysis.** Future J. Pharm. Health. Sci. 2023; 3(2): 182-185.



© 2023 Pharma Springs Publication.