



## A review of liver cirrhosis

Sk. Meharunnisa<sup>\*1</sup>, R. Johannan Immanuel<sup>2</sup>, M. Sharmila<sup>2</sup>, K. Akhila<sup>2</sup>, U. Anusha<sup>2</sup>, Sreenivasulu M<sup>3</sup>

<sup>1</sup>Department of Pharmacology, Ratnam Institute of Pharmacy, Pidathapolur Village and Post, Muthukur (M), SPSR Nellore District, Pidathapolur, Nellore, Andhra Pradesh 524346

<sup>2</sup>Doctor of Pharmacy, Ratnam Institute of Pharmacy, Pidathapolur Village and Post, Muthukur (M), SPSR District, Pidathapolur, Nellore, Andhra Pradesh 524346

<sup>3</sup>Department of Pharmaceutical Chemistry, Ratnam Institute of Pharmacy, Pidathapolur Village and Post, Muthukur (M), SPSR Nellore District, Pidathapolur, Nellore, Andhra Pradesh 524346

### Article History:

Received on: 10 Mar 2023

Revised on: 25 Mar 2023

Accepted on: 26 Mar 2023

### Keywords:

Liver cirrhosis, varices, variceal bleeding, hepatitis, alcohol, disease

### ABSTRACT

The last stage of chronic liver disease is liver cirrhosis. The condition is currently the 12th most common cause of mortality in the US. Cirrhosis is becoming more common in Germany, where it is presently one of the top 20 killers. The major causes of liver cirrhosis include autoimmune inflammation, hereditary illness, and chronic liver disease. The pathological course of liver cirrhosis is the same regardless of the initiating factors. Hepatocytes are damaged during the early inflammatory reaction, which causes necrosis and fibrosis. The loss of functioning hepatocytes reduces the liver's functionality. Although cirrhosis is a pathological diagnosis, it is often identified clinically through a patient's medical history, physical examination (looking for cutaneous symptoms of liver disease, for example), ancillary testing (ultrasonography, transient electrography), and laboratory examinations. These are not laboratory cutoff levels for the cirrhosis diagnosis. The main side effects of cirrhosis include portal hypertension, varices, encephalopathy, ascites, and hepatorenal syndrome. Therapies to minimize the risk of variceal bleeding, preserve electrolyte balance, and avoid infections are intended to treat these consequences.



### \*Corresponding Author

Name: Sk. Meharunnisa

Phone: +91 6300287608

Email: mehar.henny123@gmail.com

eISSN: 2583-116X

pISSN:

DOI: <https://doi.org/10.26452/fjphs.v3i2.461>



Production and Hosted by

Pharmasprings.com

© 2023 | All rights reserved.

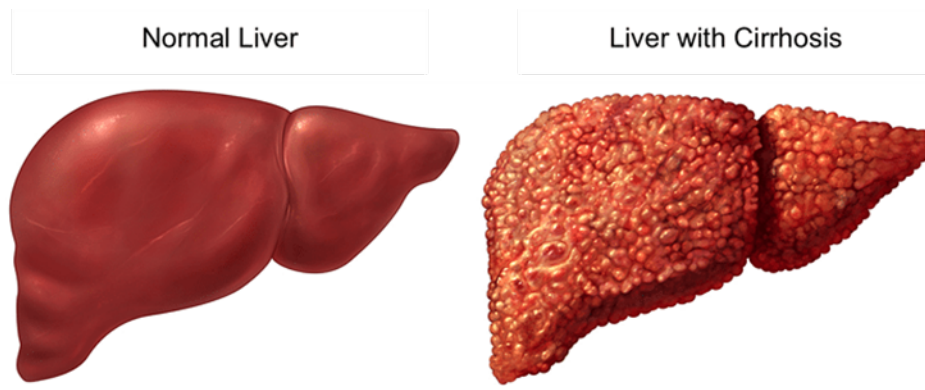
including viral infections, toxins, genetic disorders, and autoimmune processes. With each damage, the liver produces scar tissue (fibrosis) at first without losing function. After long-term damage, most of the liver tissue fibrosis, resulting in loss of operation and the development of cirrhosis [1].

**Stages of cirrhosis [2-5] :** Cirrhosis is classified into two phases: compensated cirrhosis and decompensated cirrhosis. (clinical stages)The steps are dynamic and progressive, possibly reversible from the decompensated to the balanced setting.

### INTRODUCTION

Liver Cirrhosis is a late stage of scarring (fibrosis) of the liver caused by various liver diseases and conditions such as hepatitis and chronic alcoholism. Numerous reasons can harm the liver,

**Compensated stage:** The asymptomatic phase of compensated cirrhosis. Patients who receive compensation don't get ascites, variceal bleeding, hepatic encephalopathy, or jaundice. An average patient with compensated cirrhosis lives for more than 12 years. Varices can be utilized to differenti-



Copyright © 2010, Cogniton Studio, Inc. All rights reserved.

**Figure 1: Diagrammatic representation of Liver cirrhosis**

ate. Varices are the main predictor of prognosis for patients who have received compensation and increase the chance of decompensation.

**Decompensated cirrhosis:** Decompensated cirrhosis is the stage that follows compensated cirrhosis. Your liver is now experiencing problems due to extensive scarring.

**Jaundice:** Yellowish skin caused by bilirubin buildup in the Blood.

**Ascites:** An buildup of fluid in the peritoneal cavity that causes abdominal swelling.

**Bleeding varices:** Abnormal veins in the bottom half of the tube that runs from the throat to the stomach.

**Hepatic encephalopathy:** The loss of brain function caused by a diseased liver's inability to filter poisons from the Blood. It is most common in persons with chronic liver cirrhosis or hepatitis.

**Types of Liver Cirrhosis [6]**

There are mainly four types of cirrhosis,

**Alcoholic cirrhosis:** The most frequent type, caused by prolonged alcoholism. Scar tissue usually surrounds the portal location.

**Post-necrotic cirrhosis:** There are extensive bands of scar tissue due to the late effects of acute viral hepatitis and industrial chemical intoxication.

**Cardiac cirrhosis:** A relatively rare condition associated with severe right-sided long-term heart failure

**Epidemiology [7]**

It is the world's tenth leading cause of mortality, with a monitoring rate of 9.2 fatalities per 1000 population. Alcohol was responsible for 45% of the deaths. Alcoholic cirrhosis affects men more than

women. Men and non-whites are more likely to die from a kind of cirrhosis. Post-necrotic cirrhosis is the most common in women worldwide.

**Etiology [8]**

Cirrhosis may develop due to an external toxin, infection, toxin-allergic reaction, immunopathological reaction, vascular process, or inborn metabolic mistake. The following are the leading causes of liver cirrhosis:

Hepatitis B, C, and D are contagious diseases.

**Autoimmune:** Primary sclerosing cholangitis, autoimmune hepatitis, and biliary cirrhosis. Bile duct stenosis, recurrent bacterial cholangitis, and chronic biliary illness.

Storage diseases, including hemochromatosis, Wilson's disease, and a lack of alpha-1-antitrypsin

**Infrequent causes:** Porphyrria, medications. Alcoholic liver illnesses and nonalcoholic liver diseases are examples of fatty liver diseases.

**Cardiovascular:** Osler disease, Budd-Circhi syndrome, and right-heart failure. When paired with the patient's medical history, serological results, and histological findings, the etiology of cirrhosis can typically be determined. Liver disorders cause the progression of cirrhosis. Liver cells are harmed, and if the injury persists, liver cells begin to die. Scar tissue eventually replaces the damaged liver cells, and the liver no longer functions correctly.

**Pathophysiology of Liver Cirrhosis [9]**

Multiple cells, including hepatocytes and sinusoidal lining cells such as hepatic stellate, sinusoidal endothelial, and Kupper cells, play a role in liver cirrhosis. Endothelial cells line the Hepatic Sinusoid, and there is a gap between endothelial cells and underlined hepatocytes known as hepatic stel-

late cells. These hepatic stellate cells play a crucial role in the pathophysiology of liver cirrhosis. When hepatic stellate cells are inactivated, they function as lipid storage cells. When hepatic stellate cells are triggered by chemical mediators secreted by Kupper cells and endothelial hepatocytes. Chronic inflammation is also stimulated. These chronic inflammations contain a variety of cytokines that should be released, for example, TNF-Alpha and IL-6, which are also activated by natural poisons. Ex. Ethanol. Following liver damage, these activated hepatic stellate cells will convert into myofibroblasts. These myofibroblasts are contractile and fibrogenic, resulting in fibrosis. Hepatocyte death, inflammatory damage of standard hepatic architecture, scarring, and fibrosis

### Risk Factors [10]

Having disorders like Wilson's disease (copper accumulated in the liver). Abundant alcohol consumption. Nonalcoholic-related steatosis is a kind of fatty liver disease. Long-term use of hepatotoxic medications. Inject narcotics using razor-sharp needles. Having viral hepatitis and being overweight. A family history. Cystic fibrosis. Iron builds up in the body (hemochromatosis).

### Signs and Symptoms [11]

Loss of appetite, Weight loss, Brownish or orange color to the urine, Blood in stools, Feeling of an enlarged abdomen, Lack of hair in the body, Nasal bleeding and gums bleeding, Enlarged breast size, Widened blood vessels, Red palms, Muscle wasting, Spider angioma, Ascites, Jaundice, Dilated vessels

### Complications [12]

**Bruising and bleeding:** Cirrhosis results in the liver producing fewer or no substances necessary for blood coagulation.

**Portal hypertension:** Bruising and bleeding can happen when Blood doesn't clot properly. Another potential reason for severe bleeding that may require treatment for your life is portal hypertension. Blood from the spleen and gut is transported to the liver by the portal vein. Cirrhosis causes this flow to slow down, increasing the pressure inside the vein.

Portal hypertension can also cause fluid to build up in the legs or belly (ascites), resulting in fluid retention and swelling.

**Peritonitis:** Peritonitis is a severe bacterial illness characterized by accumulated fluid in the abdomen.

**Jaundice:** Jaundice is a yellowing of the skin and eye whites and a darkening of the urine that develops when the damaged liver cannot correctly process to

remove bilirubin from the Blood.

**Gallstones:** Gallstones are a problem for around one-third of persons with cirrhosis.

**Malnutrition:** Cirrhosis can impair the body's capacity to metabolize nutrients.

**Bone diseases:** Cirrhosis can cause bone weakness in some persons, increasing their fracture risk.

### Screening and Diagnosis [13]

Liver cirrhosis can be diagnosed based on medical history, physical examination, and the result of laboratory tests

#### Laboratory tests:

**Complete blood count:** this test can detect infections and anemia that may be brought on by internal bleeding.

**Liver function testing:** These tests can reveal abnormal liver enzyme levels, which may indicate liver disease. The following liver enzyme values are seen in liver cirrhosis: Elevated levels of alkaline phosphatase (ALP), aspartate transaminase (AST), and alanine transaminase (ALT).

Serum bilirubin concentrations are elevated.

The amount of blood proteins steadily declines.

**Imaging tests:** Imaging tests can display information on the liver's size, shape, texture, and stiffness. Scarring can be seen by evaluating the liver's rigidity. Additionally, imaging tests can demonstrate how much fat is stored in the liver.

Imaginary tests, such as magnetic resonance imaging (MRI), ultrasound, and X-rays like computerized tomography [CT], are sometimes used to diagnose liver cirrhosis.

Transient elastography is a type of ultrasonography that assesses the stiffness of the liver and the fat in the liver.

**Liver biopsy:** A tissue sample (biopsy) is removed from the liver and examined under a microscope for evidence of injury or disease.

### Preventions [14]

Complete abstinence from alcohol immediately. All patients with ascites require sodium restriction counseling. Medication use must be closely monitored for potential hepatotoxicity. Medication that is metabolized hepatically has the potential to accumulate in patients with liver disease. Nasogastric suction minimizes the risk of aspirating stomach contents in patients with variceal bleeding. During acute episodes of variceal bleeding, nasogastric suction can assist in reducing vomiting. Blood in the gastrointestinal tract is exceptionally mutating;

**Table 1: Pharmacological treatment of liver cirrhosis**

BRAND NAMES	GENERIC NAMES	DOSE/ ROUTE	DURATION	FREQUENCY	MECHANISM OF ACTION
AMOXIL	Amoxicillin	500mg/ PO	3-5 days	BD	It acts through the inhibition of cell wall biosynthesis that, lead to the death of the bacteria
CIPLOX	Ciprofloxacin	500 mg/ PO	3-5 days	BD	It is active against some gram-positive and gram-negative bacteria
RIFAGUT	Rifaximin	550mg/ PO	3-5 days	BD	It has antibacterial activity against some gram-positive and gram-negative microorganisms. It inhibits bacterial protein synthesis by irreversibly binding to RNA polymerase.
VIREAD	Tenofovir	300 mg/ PO	3-7 days	OD	It prevents viral replication by competing with natural nucleotides for binding to the active site of HBV polymerase.
BARACLUDE	Entecavir	0.5 mg/ PO	3-7 days	OD	In the viral replication process, it inhibits reverse transcriptase, DNA transcription, and replication.
TENORMIN	Atenolol	25-50 mg/po	7-10 days	OD	Portal pressure rises, spleen hyperemia develops, SNS activity increases, and bacterial translation occurs.
MET XL	Metoprolol succinate	25 mg/ PO	5-7 days	BD	preventing initial and subsequent variceal bleeding in cirrhotic individuals
INDERAL	Propranolol	20-40 mg/ PO	5-7 days	BD	By inhibiting beta-2 receptors, causing splanchnic vasoconstriction, and decreasing portal flows
BUMEX	Bumetanide	2mg/po	5-6days	OD	primarily enhances the excretion of water, sodium, and chloride through the urine. Impede the reabsorption of sodium and chloride
LASIX	Furosemide	20mg/ po	5-6days	OD	Lasix inhibits the sodium-potassium cotransporter.
HYDROCHLOROT	Hydrochlorothiazide	25-100MG/PO	3-5days	BD	It blocks the transport of sodium chloride.
DUPHALAC	Lactulose	10-20mg/ day	5-7 days	BD	It transfers ammonia from the Blood to the colon, where the body excretes it.

removing the Blood can minimize vomiting. Keep a healthy weight. An excess of body fat might harm your liver. Lower your risk of hepatitis. Toxins occur in the digestive tract as a result of protein. As a result, eating less protein will reduce the accumulation of toxins in the Blood and brain.

## CONCLUSION

In this article, we conclude the main etiological factors and complications of liver cirrhosis, as well as the observation of elevated levels of liver enzymes, and we list the effective medications for this disease. (liver cirrhosis)

## Acknowledgement

We thank our principal, Dr. M. Srinivasulu Reddy, for supporting and guiding us in writing this review article.

## Conflict of Interest

The authors declare no conflict of interest, financial or otherwise.

## Funding Support

The authors declare that they have no funding support for this study.

## REFERENCES

- [1] Cristina Roberto Giulio Romanelli and Stasi. Recent Advancements in Diagnosis and Therapy of Liver Cirrhosis. *Current Drug Targets*, 17(15):1804–1817, 2016.
- [2] Manfred Gross, 2015.
- [3] Xing Wang and Bin Wu. Critical issues in the diagnosis and treatment of liver cirrhosis. *Gastroenterology Report*, 7(4):227–230, 2019.
- [4] Philipp Kasper, Frank Tacke, and Guido Michels. Action algorithm: decompensated alcoholic liver cirrhosis in the emergency department. *Medizinische Klinik - Intensivmedizin und Notfallmedizin*, 117(7):568–570, 2022.
- [5] J Flores-Calderon, L E Cisneros-Garza, J Chávez-Barrera, F A Vazquez-Frias, D Reynoso-Zarzosa, Martínez-Bejarano, Consuelo-Sanchez, F E Reyes-Apodaca, M P Zarate-Mondragon, R I Alcantara-Garcia Sanchez-Soto, S Gonzalez-Ortiz, and Ledesma-Ramirez. Consensus Statements Consensus on the management of complications of cirrhosis of the liver in pediatrics. *Revista De Gastroenterologia De Mexico*, 87(4):462–485, 2022.
- [6] P Schirmacher, Fleig, C Tannapfel, V Langner, Dries, H Terracciano, P Denk, and Dienes. Biop-tic diagnosis of chronic hepatitis. Results of an evidence-based consensus conference of the German Society of Pathology, the German Society for Digestive and Metabolic Diseases, and Compensated Hepatitis (HepNet). *Pathology*, 25(5):337–348, 2004.
- [7] Chun-Tao Wai, Joel K Greenon, Robert J Fontana, John D Kalbfleisch, Jorge A Marrero, Hari S Conjeevaram, and Anna S-F Lok. A simple, noninvasive index can predict significant fibrosis and cirrhosis in patients with chronic hepatitis C. *Hepatology*, 38(2):518–526, 2003.
- [8] F Imbert-Bismut, V Ratziu, Pieroni, Y Charlotte, T Benhamou, ; Poynard, and Multivirc Group. Biochemical markers of liver fibrosis in patients with hepatitis C virus infection: a prospective study. *Lancet*, 357(9262):1069–1075, 2001.
- [9] Hiroshi Fukui, Hidetsugu Saito, Yoshiyuki Ueno, Hirofumi Uto, Katsutoshi Obara, Isao Sakaida, Akitaka Shibuya, Masataka Seike, Sumiko Nagoshi, Makoto Segawa, Hirohito Tsubouchi, Hisataka Moriwaki, and Akinobu Kato. Evidence-based clinical practice guidelines for liver cirrhosis. *Journal of Gastroenterology*, 51(7):629–650, 2015.
- [10] E I R Wanless, M Nakashima, and Sherman. Regression of human cirrhosis.Morphologic features and the genesis of incomplete septal cirrhosis. *Archives of Pathology and Laboratory Medicine*, 124(11):1599–607, 2000.
- [11] C Geoffrey, Claire Z Farrell, and Larter. Non-alcoholic fatty liver disease: from steatosis to cirrhosis. *Hepatology*, 43(2):99–112, 2006.
- [12] M Pirovino, C Linder, H P Boss, F Kochli, and Mahler. Cutaneous spider nevi in liver cirrhosis: Capillary microscopical and hormonal investigations. *Klin Wochenschrift*, 66(7):298–302, 1988.
- [13] J A P G Foutch, J A Sullivan, R A Gaines, and Sanowski. Cutaneous vascular spiders in cirrhotic patients: correlation with bleeding from esophageal varices. *American Journal of Gastroenterology*, 83(7):723–726, 1988.
- [14] W J Powell Jr and G Klatskin. Duration of survival in patients with Laennec’s cirrhosis. Influence of alcohol withdrawal, and possible effects of recent changes in general disease management. *American Journal of Medicine*, 44(3):406–420, 1968.

**Copyright:** This is an open access article distributed under the terms of the Creative Commons Attribution-NonCommercial-ShareAlike 4.0 License, which allows others to remix, tweak, and build upon the work non-commercially, as long as the author is credited and the new creations are licensed under the identical terms.

**Cite this article:** Sk. Meharunnisa, R. Johannan Immanuel, M. Sharmila, K. Akhila, U. Anusha, Sreenivasulu M. A review of liver cirrhosis. Future J. Pharm. Health. Sci. 2023; 3(2): 141-146.



© 2023 Pharma Springs Publication.