








FUTURE JOURNAL OF PHARMACEUTICALS AND HEALTH SCIENCES

Published by Pharma Springs Publication | Journal Home Page: <https://pharmasprings.com/fjphs>

A Review of Health-Promoting Properties of *Cassia occidentalis*

Sai Koteswar Sarma D¹, Deepak Kumar², Vyshnavi V³, Naveen N³, Shaik Fousia³,
Vishnu Vardhan S³

¹Department of Pharmacognosy, Sri Padmavathi School of Pharmacy, Vaishnavi Nagar, Tiruchanoor, Tirupati - 517503, Andhra Pradesh, India

²Krishna Institute of Pharmacy, Dhanbad - 828402, Jharkhand, India

³Sri Padmavathi School of Pharmacy, Vaishnavi Nagar, Tiruchanoor, Tirupati - 517503, Andhra Pradesh, India

Article History:

Received on: 10 Mar 2023

Revised on: 25 Mar 2023

Accepted on: 26 Mar 2023

Keywords:

Cassia occidentalis,
Pharmacological
Activities

ABSTRACT



Cassia occidentalis is a widespread and widely utilized plant. It grows in the southern parts of India. It belongs to the Sakavarga family of medicinal plants, including spices, vegetables, and herbs. This herb, known as Kasamarda in Sanskrit, is effective for treating skin disorders, relieving constipation, and curing worm-related diseases. It has an antiallergic, antibacterial, antidote for poison, blood purifier, antifungal, antidiabetic, anti-inflammatory, antimutagenic, psoriasis, melanoblast cell line leprosy, and hepatoprotective properties. The chemicals include Achrosin, aloe emodin, cassia occidental I, Cassia occidental II, emodin, anthraquinones, anthrones, apigenin, guaranty obtain, campesterol, cassiollin, chrysophanic acid, chrysoarobin, chrysophanol, chrysoberyl. Its aerial portions have favorable physicochemical qualities with high nutritional value, such as increased energy, crude fibers, and vitamin levels. The data from X-ray fluorescence spectrophotometry revealed that the sample is rich in minerals, particularly Fe, Ca, K, and Mn. Furthermore, minerals such as Mg, Zn, Cu, Na, P, and S are abundant and demonstrate the nutritional value of the chosen material. Flavonoids, alkaloids, lignin, tannins, and phenols are abundant in the plant sample. The present study will highlight all the properties and therapeutic uses, toxicological studies, nutrition value, and mainly the pharmacological activities of *C. occidentalis*.

*Corresponding Author

Name: Sai Koteswar Sarma D

Phone: +91 90523 33068

Email: sarmaspsp@gmail.com

eISSN: 2583-116X

pISSN:

DOI: <https://doi.org/10.26452/fjphs.v3i2.438>



Production and Hosted by

Pharmasprings.com

© 2023 | All rights reserved.

INTRODUCTION

In Ayurveda, In ayurveda and Unani, *Cassia occidentalis* is known as Kasamarda and Kasaondi

(Kasundi), respectively. In Sanskrit, the words Kasa and Mardan both indicate to demolish or cough out mucus. Therefore, the one who destroys Kasa is known as Kasamarda [1]. A Siddha is known as Paeyavarai, Thagarai [Figure 1].

Cassia occidentalis L. (Leguminosae) A "famine food" or "edible weed of agriculture." The nighandus rajnighantu, Dhanwantari, Bhavaprakasa, Rajbal-laba, etc., all reference *C. occidentalis*, commonly known as "kasamarda." Locals frequently use this plant as a replacement for coffee. It is an erect, stinky, annual herb or under a shrub, 60-150cm in height, found throughout India up to an altitude of 1500 m. Leaves are 15-20 cm long and lanceolate or ovate-lanceolate, leaflets three pairs, membranous, glaucous, ovate, or lanceolate (Plate 5.1 II d); flowers

yellow, in short racemes, pods recurved, seeds are dark olive green and elliptical, complex and smooth shining [2].

The presence of the primary phytochemicals in *C. occidentalis* includes acrosin, aloe-emodin, emodin, islanding, kaempferol, obtusifolin, obtain, and physcion, as well as anthraquinones, apigenin, aurantiobtusin, campesterol, cassiollin, chrysoobtusin, chrysacording to the temperature and soil characteristics of the growing region, the kind and quantity of phytochemicals in *C. occidentalis* vary. For instance, the plant's stems, leaves, and root bark from the Ivory Coast, Africa, do not contain any alkaloids. Yet, many alkaloids were discovered in the samples from Ethiopia. *C. occidentalis* L. is used extensively in traditional medicine and ethnic cuisine, but little is known about its physicochemical makeup and nutritional value. As a result, efforts were made in the current research to investigate the physicochemical characteristics and nutritional profile of *C. occidentalis* L [3].

Botanical Description

It occurs in West Bengal, South India, Burma, and Ceylon. All tropics and subtropics, including the eastern United States from Texas to Iowa, Africa, Asia, and Australia, support the growth of coffee senna. On wastelands, right after the rains, prolific growth. The plant *Cassia occidentalis* a common weed with subglabrous branches, a diffuse pungent under shrub, and leaflets. Yellow flowers. This species may be found across India, up to a height of 1.500 mt, from the Himalayas to the -5 pairs, cylindrical or compressed fruits, and transversally septate, glabrous pods with 20–30 seeds. The entire plant includes leaves, flowers, and fruit [4] [Figure 2].

The plant is an annual tropical herb with leathery compound leaves that can reach heights of 6 feet. The olive-brown seeds are flattened on both ends and have dark brown seed pads that bend slightly upward. Long pods containing the seeds may be roasted and turned into a beverage like coffee. Each 4-6 pairs of almost sessile, opposite leaflets on an alternating, even pinnately compound leaf is 4-6 cm long, 1.5–2.5 cm broad, ovate or oblong, lanceolate with a pointy tip, and delicate white hairs on the border. When crushed, the leaflets emit a foul odor. A large, ovoid, shiny, dark purple gland is at the base of the rachis. The 5–10 mm long stipules frequently leave an oblique scar on the skin. An inflorescence is a combination of axillary and terminal racemes [5]. The flower is flawless, measuring 2 cm long, and has five yellow petals and five yellowish-green sepals with pronounced red veins. The fruit is a sickle-

shaped legume (pod), dry, dehiscent, transversely partitioned, hardly recurved, laterally compressed, with a rounded tip, and carrying 25–50 seeds. Oval-shaped, 3.5-4.5 mm broad, flattened seeds have a round, pointy end, are smooth, pale to dark brown, and can be glossy.

In Thailand, the *Cassia occidentalis* [6] is referred to by various common names depending on the region, language, or district. One such name is Chumhettet. Nepalese words like Barkichakor, Chilmile, Panwar, and Tulotapre.

Negro coffee in English, Kasaumdi in Hindi, Ponnavirm in Malayalam, Kasamardah in Sanskrit, and Kasinda in Telugu.

Taxonomy

Plantae - Kingdom of Plants

Subkingdom: Vascular plants (Tracheobionta)

Spermatophyta: A subclass of seed plants

Magnoliophyta: The order of flowering plants

Magnoliopsida: Dicotyledons as the class

subclass: Rose family

Family: Leguminosae

Family: Leguminosae

Caesalpinia L. nicker species *Cassia occidentalis* is part of the genus.



Figure 1: Image of *Cassia occidentalis* L. (Leguminosae)

Uses

Due to its numerous medical benefits, *Cassia occidentalis* has historically been utilized as a febrifuge, tonic, diuretic, anthelmintic, and purgative. It is a folk remedy for sexual illnesses, fevers, piles, colic discomfort, dropsy, and rheumatism. It is applied topically to treat eczema, ringworm, and other skin conditions. It is also known as Coffee Senna or Negro Coffee because the tree seeds are roasted and ground to make strong coffee. The seeds are also used to treat heart conditions and whooping cough. Roots lose their ability to purge when they



Figure 2: Plant of *Cassia occidentalis* L. (Leguminosae)

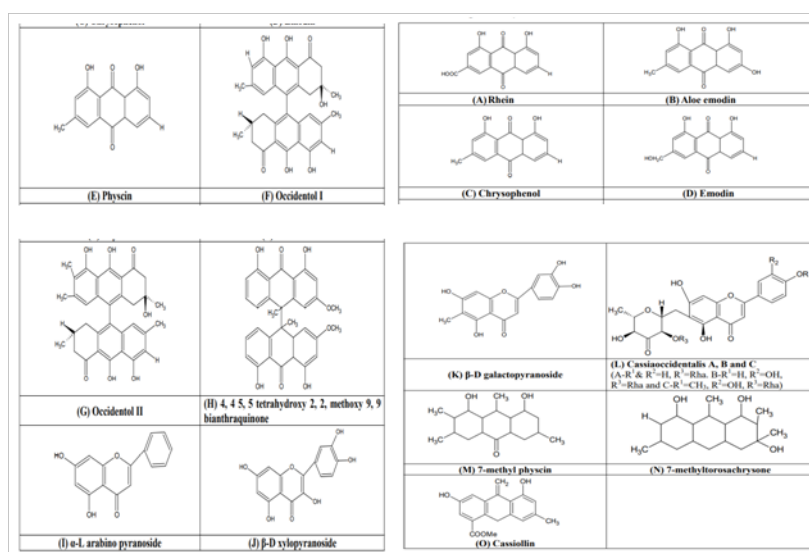


Figure 3: Chemical Structures of Flavanoids, Carotenoids and Phenolics

are burned. This coffee is prescribed as a tonic, a replacement for coffee, and a treatment for asthma, convulsions, and hysteria [7]. *C. occidentalis* L. is used extensively in traditional medicine and ethnic cuisine, but little is known about its physicochemical makeup and nutritional value. Therefore, in the current article, efforts were made to use modern methodologies to investigate the physicochemical characteristics and nutritional profile of *C. occidentalis* L [8] [Table 1].

Chemical Constituents

Crude lipid 14.9%, natural fiber 20.8%, crude protein 2.3%, and carbs 48.1% were all present in the plant. Anthraquinone, proteins, phlorotannins, steroids, tannins, flavonoids, anthraquinones,

saponins, terpenes, resins, balsams, amino acids, carbohydrates, sugars, and cardiac glycosides were among the chemical groups found in the various plant parts, according to the phytochemical analysis [9].

Numerous substances were discovered in *Cassia occidentalis*, including achrosin, aloe-emodin, emodin, anthrones, apigenin, aurantiobtusin, campesterol, cassiolin, chryso-obtusin, chrysophanic acid, chrysarobin, chrysophanol, chrysoeriol, rhein, aloe [10].

From the seeds of *Cassia occidentalis* Linn, three novel chemicals were extracted. These substances have been identified as 5-O-dxylopyranosyl-7-O-l-rhamnopyranosyl-5, 7-dihydroxyflavone (1 3)

Table 1: Ethanol Medicinal Uses

Regions	Ethano Medicinal Use
India	Abscesses, bites (scorpion), constipation, diabetes, edema, fever, inflammation, itch, liver diseases, liver support, rheumatism, ringworm, scabies, skin diseases, snake bite, wounds
Africa	Abscesses, bile complaints, birth control, bronchitis, bruises, cataracts, childbirth, constipation, dysentery, edema, erysipelas, eye infections, fainting, fever, gonorrhea, guinea worms, headache, hematuria, hemorrhages (pregnancy), hernia, increasing perspiration, inflammation, itch, jaundice, kidney infections, leprosy, malaria, pain (kidney), menstrual disorders, rheumatism, ringworms, scabies, skin diseases, skin parasites, sore throat, stomach ulcers, stomach ache, swelling, syphilis, tetanus, worms, water retention, wounds
Brazil	Anemia, constipation, edema, fatigue, fever, gonorrhea, liver disorders, malaria, Menstrual disorders, skin problems, tuberculosis, urinary disorders, water retention, weakness
Central America	Abortions, antifungal, athlete's foot, birth control, constipation, diarrhea, fungal infections, headache, menstrual disorders, menstrual pain, pain, respiratory infections, ringworm, spasms, uterine pain, urinary tract infections, urinary insufficiency, worms
Mexico	Chills, digestive sluggishness, dyspepsia, ear ache, eczema, edema, fatigue, fever, headache, inflammation (skin), laxative, leprosy, nausea, pain, rash, rheumatism, ringworms, skin problems, sores, stomachache, swelling, tumors, ulcers, venereal disease, water retention, worms, yellow fever
Panama	Colic, inflammation, spasms, stomach problems, worms, and as an antiseptic
Haiti	Acne, asthma, burns, colic, constipation, dropsy, eye infections, gonorrhea, headache, malaria, rheumatism, skin rashes and infections, and to increase perspiration
Amazonia	For abdominal pain, birth control, bile insufficiency and malaria
Peru	For asthma, bronchitis, fever and urinary insufficiency

5, 7, 3', 4'-tetrahydroxy-6-methoxyflavone-5-O-l-arabinopyranoside, 3, 5, 7, 3', 4'-pentahydroxy flavone-3-O-l-rhamnopyranosyl-7-O-d-glucopyranosyl-(1-3)-O-d-xylopyranoside, and 5-O-l-arabinopyr (1-4) O-l-rhamnopyranosyl-(1-3)-D-galactopyranoside. There are two novel anthraquinone glycosides: 1,3-dihydroxy-6,7,8-trimethoxy and -2-methylanthraquinone 1-hydroxy-3,6, 7,8-tetramethoxy and 3-O-rhamnopyranosyl(1-6)-glucopyranosyl (1-6)-galactopyranoside 2-methyl anthraquinone. From the leaves of *Cassia occidentalis*, 1-O-rhamnopyranosyl (1,6)-glucopyranosyl (1,6)-galactopyranoside has been extracted [11]. Glycosides 3,2'-dihydroxy-7,8,4'-trimethoxyflavone-5-O-Dglucopyranosyl (1-2)-D-galactopyranoside. From *Cassia occidentalis*, apigenin-7-O-D-allopyranoside has been isolated [12].

Total flavonoids were 3.24 g/g, carotenoids were 2.9 g/g, and total phenolics were 6.7 g in the extract of *Cassia occidentalis*. The total yield of *Cassia occidentalis* oils was 1.0%, the iodine value was 114.5, the thiocyanogen value was 74.0, the saponification equivalent was 283.0, the yield percentages for liquid fatty acids were 74.9, the iodine value was 151.3, the saponification equivalent was 280.5, the yield percentage for solid fatty acids was 25.1, the iodine value was 3.8, and the yield percentage for saturated acids was 24.0. Defatted *Cassia occidentalis* flour's mineral makeup contained Ca 3.81, Na 0.11, K 1.86, and Mg 0 [Figure 3].

Pharmacological Activity

Antimicrobial Activity

At concentrations between 900 and 1000 mg, leaf extracts of *Cassia occidentalis* produced in vari-

ous solvents demonstrated vigorous antibacterial activity against *E. coli*. No antimicrobial activity was reported against the other tested microorganisms (*Pseudomonas multocida*, *Salmonella typhi*, *Salmonella typhimurium*, *Salmonella pyogenes*, and *Salmonella pneumonia*). Still, it was discovered that The concentration ranges of a hexane extract where *E. coli* was most sensitive were between 500 and 1000 mg. Additionally, another study examined the leaf, seed, and pod for the antifungal activity of the fungus, except for the leaf extract's anti-*Aspergillus* efficacy, nystatin, and Griseofulvin was investigated [13].

Different organic and aqueous extracts of *Cassia occidentalis* L leaves were tested for antimicrobial activity by disc diffusion assay against seven human pathogenic bacterial strains and two fungal strains, including *P. aeruginosa*, *K. pneumoniae*, *P. mirabilis*, *E. coli*, *S. aureus*, *S. epidermidis*, and fungus *C. albicans*. The most susceptible microorganisms were *Candida albicans* (8 mm inhibition zone in methanol extract), *P. mirabilis* (15 mm zone of inhibition), as well as *P. aeruginosa* (18 mm zone of inhibition in aqueous extract). Methanol and aqueous extracts demonstrated significant antimicrobial activity against most of these microorganisms [14].

Using the agar well diffusion technique at a range of doses (80-360 mg/ml), the antibacterial effects of *Cassia occidentalis* were examined against *Escherichia coli*, *Klebsiella pneumoniae*, *Candida albicans*, *Staphylococcus aureus*, *Pseudomonas aeruginosa*, and *Salmonella typhi*.

The minimal bactericidal concentration (MBC) was obtained by plating different extract dilutions, whereas The serial dilution technique was used to establish the least inhibitory concentration (MIC). The extract showed that *S. aureus* and *P. aeruginosa* were the most sensitive organisms, while *K. pneumoniae* showed some resistance compared to the other tested organisms [15]. Substantial antibacterial activity was observed with MIC values between 160 and 280 mg/ml, and MBC values between 160 and 320 mg/ml were reported.

Central Nervous System Depressant

The leaf ethanol extract of *Senna occidentalis* possesses a CNS depressant effect was showed [11].

Anti-Inflammatory Activity

Another study examined the anti-inflammatory properties of a methanolic extract of *Cassia italica* leaves in animal models. For pharmacological testing, the leaves of *Cassia occidentalis* Linn have been collected through cold extraction with a mixture of equal parts petroleum ether, ethyl acetate,

and methanol. The extract demonstrated effective anti-inflammatory action at various dosages, which was significantly done by edema development brought on by carrageenan and formulation. The section at 400 mg/kg dose level demonstrated 36.68% (p0.001) suppression of edema volume at the end of 4 hours in the rat paw edema model caused by carrageenan [6].

Anticonvulsant Activity

According to research, the *Cassia occidentalis* Linn plant's chloroform extract has exceptional anticonvulsant effectiveness against MES and PTZ-induced convulsion [16].

Anti-Diabetics' Activity

In additional research, it was found that the root extract of *Cassia occidentalis*, 400 mg/kg, did not significantly differ from that of the animal group treated with aqueous extract, which significantly decreased Fasting blood sugar levels in diabetic as well as healthy rats produced by alloxan and mice, respectively. The leaf extract also significantly reduced blood glucose levels to normal in diabetic mice. According to the current study, the section has the ability to lower blood sugar levels and treat dyslipidemia brought on by hyperglycemia. The methanol fraction of plant leaves (COLMF) was tested against streptozotocin-induced diabetic rats, and this discovery scientifically supports its application in conventional medicine for the treatment of diabetes [4].

Nephroprotective Activity

The 70% hydroalcoholic *Cassia occidentalis* Linn extract was investigated for its ability to protect rats' kidneys against gentamicin-induced nephrotoxicity.

Calculations of urine Blood urea, serum creatinine levels, urine glucose, urinary sodium, urinary potassium, and animal body weight were used to assess the amount of protection.

GSH, SOD, catalase, and lipid peroxidation tissue levels were evaluated to determine the in-vivo antioxidant activity. The findings indicated that HACO had nephroprotective action against kidney injury from gentamicin [12].

Antitrypanosomal Activity

A related investigation examined the ethanol extract of *Senna occidentalis* leaf in vitro and in vivo antitrypanosomal properties.

The motility of the parasites was entirely eradicated within 10 minutes of the end of the incubation period when the crude extract, which had an adequate concentration of 6.66 mg/ml, was used [3].

Myostimulant Effect

It has been shown that the biostimulant action of *Cassia occidentalis* leaves is characterized by an increase in the rhythm and amplitude of isolated intestinal muscle [14].

Cytotoxicity Activity

In a subsequent investigation, alcoholic, hydroalcoholic, and aqueous extracts of plants were used to test their in vitro cytotoxicity and antibacterial effects against eight human cancer cell lines from six distinct tissues and four bacterial strains. Concerning Human cancer, cell lines HCT-15, SW-620, PC-3, MCF-7, SiHa, and OVCAR-5 were tested. Aqueous extract was discovered to perform better than hydroalcoholic and alcoholic extracts at concentrations of 100, 30, and 10 g. In a separate study, the hydroalcoholic section of seeds on clonidine-induced mast cell degradation was investigated and compared with the effect of oral administration of sodium cromoglycate as the gold standard on rats. Mast cell degeneration was the outcome of clonidine [5].

Antipyretic and Antioxidant Activity

Additionally, evaluation based on the antipyretic and antioxidant properties of the methanolic seed extract of the plant using several in-vitro models. The antioxidant potency of Several successive models in vitro systems, including nitric oxide scavenging (NOS) activity, the carotene-linoleic acid model system, hydroxyl radical scavenging (HRS) activity, reducing power, and metal chelating activity, were used to study organic and aqueous leaf extracts of *Cassia occidentalis* (MCA). Lastly, antioxidant and antipyretic properties (DPPH and Hydrogen Peroxide Method) [17].

Toxicological Studies

A few studies examined the effects of subacute oral administration of the plant during pregnancy in female Wistar rats.

In a related study, male and female Wistar rats were used in a pre-clinical safety evaluation of the hydroalcoholic extract of the plant's stem and leaves. Both groups of rats showed no toxicity, indicating a safe use in humans [18].

Effect on Smooth Muscles Contraction

When the endothelium is intact or not in rat aortic rings, the relaxing effects of an aqueous *Cassia occidentalis* leaf extract were studied. Noradrenaline (NA) and potassium chloride (KCl) both suppressed contraction in the section dose-dependent manner.

Aortic rings precontracted with 10⁻⁷ M NA and 50m M KCl were likewise relaxed. The prostacy-

clin inhibitor indomethacin and the dye methylene blue did not affect the induced relaxation, which was not dependent on the existence of an intact vascular endothelium [9].

Toxicology/Pharmacokinetics

The clinical and histological results of a horse poisoning epidemic caused by *C. occidentalis* were investigated. After ingesting ground corn that contained 8%.

occidentalis seeds, twenty mares became ill. Of the 20 animals afflicted, 12 passed away. Of the two deaths that occurred within 6 hours of the beginning of clinical indications consistent with hepatic encephalopathy, other animals were put to death 12 hours after the onset of the clinical signs. On the other hand, the remaining eight mares showed signs of moderate sadness and decreased appetite, but they got well with therapy, and no clinical consequences were seen. An increased hepatic lobular pattern and many seeds were seen in the large intestines of 6 animals that underwent necropsies [19]. The primary histopathological findings have been cerebral edema and hepatocellular pericentrolobular necrosis. There has been minor multifocal in one foal semi-membrane abduomyocytic necrosis and haemorrhage. The seeds removed from the guilty feed ingredient and sorted from digestive contents were inspected. Analysis of the resulting plant's leaves, flowers, fruits, and seeds revealed *C. occidentalis*. Horses poisoned with *C. occidentalis* seeds exhibit hepatoencephalopathy-related clinical symptoms or frequently pass away abruptly. The liver is affected most often, followed by the CNS [7].

Fresh or dry beans are poisonous, as shown by several animal experiments. Large quantities being consumed by grazing animals have resulted in fatal illnesses. Several mechanisms are engaged depending on the animal type and the amount of beans ingested. The skeletal muscles, liver, kidney, and heart are the organs most affected by toxicity in big animals, rodents, and fowl. Frequently, brain functions were impacted. Skeletal muscle fiber necrosis and hepatic centrilobular necrosis are the two most common gross lesions found after necropsy; renal tubular necrosis was less common. Biochemical abnormalities were reflected in the necrosis of muscle and liver cells. The median fatal dosage (LD50) for mice and rats is 1 g/kg. Numerous anthraquinones, their derivatives, and alkaloids have been linked to toxicity [13].

Toxic and Adverse Effects

The clinical and histological results of a horse poi-

soning epidemic caused by *C. occidentalis* were investigated. After ingesting ground corn that contained 8% *C. occidentalis* seeds, twenty mares became ill. Of the 20 animals afflicted, 12 passed away. Of the two deaths that occurred within 6 hours of the beginning of clinical indications consistent with hepatic encephalopathy, other animals were put to death 12 hours following the onset of the clinical symptoms [20]. On the other hand, the remaining eight mares showed signs of moderate sadness and decreased appetite, but they got well with therapy, and there were also no clinical consequences. An increased hepatic lobular pattern and many seeds were seen in the large intestines of 6 animals that underwent necropsies. The primary histopathological findings were cerebral edema and hepatocellular pericentrolobular necrosis. Mild multifocal semi-membranous abduomyocytic necrosis and haemorrhage were present in one mare. The seeds removed from the guilty feedstuff and sorted from digestive contents were inspected. Examination of the resulting plant's leaves, flowers, fruits, and seeds revealed *C. occidentalis*. Horses poisoned with *C. occidentalis* seeds exhibit hepatoencephalopathy-related clinical symptoms and commonly pass away abruptly. A liver and CNS are affected most frequently by lesions [21].

CONCLUSION

This investigation showed that the chosen plant has significant energy value, crude fibres, vitamins, minerals, particularly iron and zinc, and antioxidant enzymes. As a result, *C. occidentalis* is a safe, wholesome, and functional dietary supplement. The sample possesses several advantageous physicochemical properties, including a high ash concentration, solubility in water, and extract yield. The physicochemical characteristics discovered in this study may be utilized as quality control measures and will help identify and authenticate this plant material.

ACKNOWLEDGEMENT

The corresponding author desires to explicit utmost gratitude to the Management and Prof. Dr. D. Ranganayakulu, M. Pharm., Ph.D., Principal, Sri Padmavati school of pharmacy, Tiruchanoor, Andhra Pradesh, India, for presenting all the necessary laboratory demands of the research and constant support.

Conflict of Interest

The authors declare no conflict of interest, financial or otherwise.

Funding Support

The authors declare that they have no funding support for this study.

REFERENCES

- [1] M C Mahanthesh et al. The chemical contents and pharmacological effects of *Anagallis arvensis* - A review. *International Journal of Pharmacy*, 5(1):37-41, 2015.
- [2] U Veerachari and A K Bopaiah. Phytochemical investigation of the ethanol, methanol and ethyl acetate leaf extracts of six *Cassia* species. *International Journal of Pharma and Bio Sciences*, 2(2):260-270, 2012.
- [3] A S Saganuwan and M I Gulumbe. Evaluation of in-vitro antimicrobial activities and phytochemical constituents of *Cassia occidentalis*. *Animal Research International*, 3(3):566-569, 2006.
- [4] S Y Daniyan, M E Abalaka, S A Aransiola, and O M Elemba. Phytochemical screening, proximate analysis and mineral composition of *Cassia occidentalis* seed extract. *Asian Journal of Pharmaceutical and health Sciences*, 1(3):145-147, 2011.
- [5] P R Yeragamreddy, R Peraman, Chilamakurub, and H Routhu. In vitro Antitubercular and Antibacterial activities of isolated constituents and column fractions from leaves of *Cassia occidentalis*, *Camellia sinensis* and *Ananas comosus*. *Afr J Pharmacol Ther*, 2(4):116-123, 2013.
- [6] T Hatano, S Mizuta, H Ito, and T Yoshida. C-glucosidic flavonoids from *cassia occidentalis*. *Phytochemistry*, 52:1379-1383, 1999.
- [7] M Gowrisri, S Kotagiri, Sbm Vrushabendra, S P Archana, and K M Vishwanath. Antioxidant and nephroprotective activities of *Cassia occidentalis* leaf extract against gentamicin induced nephrotoxicity in rats. *Research Journal of Pharmaceutical, Biological and Chemical Sciences*, 3(3):684-694, 2012.
- [8] S Shafeen, R T Srinath, S Arafath, S Nagarjuna, and R Y Padmanabha. Evaluation of antianxiety and antidepressant activity of *Cassia occidentalis* leaves. *Asian Journal of Pharmacy and Clinical Research*, 5:47-50, 2012.
- [9] S Emmanuel et al. Antidiabetic activity of *Cassia occidentalis* Linn. in streptozotocin-induced diabetic rats: A dose dependent study. *International Journal of Pharma and Bio Sciences*, 1(4):14-25, 2010.

- [10] A A Nuhu and Aliyu R. Effects of Cassia occidentalis aqueous leaf extract on biochemical markers of tissue damage in rats. *Tropical Journal of Pharmaceutical Research*, 7(4):1137–1142, 2008.
- [11] O P Ajagbonna, P A Onyeyili, V A Osunkwo, and Muhammed By. Acute toxicity and phytochemical studies of Cassia occidentalis Linn extract in rats. *Sokoto Journal of Veterinary Sciences*, 2(2):32–35, 2000.
- [12] I S Sadiq, M Shuaibu, A B Bello, S G Tureta, A Isah, T Izuagie, S Nasiru, and Kamaru Mb. Phytochemistry and antimicrobial activities of Cassia occidentalis used for herbal remedies. *Journal of Chemical Engineering*, 1(1):38–41, 2012.
- [13] A V S Sastry, V G Sastry, B Appalanaidu, K Srinivas, and A Annapurna. Chemical and pharmacological evaluation of aqueous extract of seeds of Cassia occidentalis. *Journal of Chemical and Pharmaceutical Research*, 3(2):566–575, 2012.
- [14] S Y Daniyan, J B Oloruntimelehin, and O Ifeadi. Antibacterial activity of Cassia occidentalis flower vegetable extract on selected bacteria. *Asian Journal of Biomedical and Pharmaceutical Sciences*, 1(1):23–27, 2011.
- [15] J Ranjithkuma, K Sivasankari, and T Sekar. Secondary metabolites investigation and its derivatives on Cassia occidentalis. *Journal of Chemical and Pharmaceutical Research*, 2(4):371–377, 2010.
- [16] S A V Ambikapathy and A P Selvam. Studies on the phytochemistry, antimicrobial activity and antioxidant properties of Cassia occidentalis L. *Asian Journal of Plant Science and Research*, 2(4):530–533, 2012.
- [17] R Gautam and Navneet Ss. Antibacterial and phytochemical analysis of Cassia occidentalis L. seeds against respiratory tract pathogens. *Indian Journal of Natural Products and Resources (IJNPR)*, 5(1):52–55, 2014.
- [18] M M Onakpa and O P Ajagbonna. Antidiabetic potentials of Cassia occidentalis leaf extract on alloxan induced diabetic albino mice. *International Journal of PharmTech Research*, 4(4):1766–1769, 2012.
- [19] J Sadique, T Chandra, V Thenmozhi, and V Elango. Biochemical modes of action of Cassia occidentalis and Cardiospermum halicacabum in inflammation. *J Ethnopharmacol*, 19(2):201–212, 1987.
- [20] M A Jafri, M Jalissubhani, K Javed, and S Singh. Hepatoprotective activity of leaves of Cassia occidentalis against paracetamol and ethyl alcohol intoxication in rats. *J Ethnopharmacol*, 66(3):355–361, 1999.
- [21] J P Oliveira-Filho, D Q Cagnini, P R Badial, M A Pessoa, Delpiero Fand Borges, and A S. Hepatoencephalopathy syndrome due to Cassia occidentalis (Leguminosae, Caesalpinioideae) seed ingestion in horses. *Equine Vet J*, 45(2):240–244, 2013.

Copyright: This is an open access article distributed under the terms of the Creative Commons Attribution-NonCommercial-ShareAlike 4.0 License, which allows others to remix, tweak, and build upon the work non-commercially, as long as the author is credited and the new creations are licensed under the identical terms.

Cite this article: Sai Koteswar Sarma D, Deepak Kumar, Vyshnavi V, Naveen N, Shaik Fousia, Vishnu Vardhan S. **A Review of Health-Promoting Properties of Cassia occidentalis.** Future J. Pharm. Health. Sci. 2023; 3(2): 118-125.



© 2023 Pharma Springs Publication.